

Efficiency of Argon Laser and Bevacizumab (Avastin) in Treatment of Corneal Neovascularization in Experimental Animal Models

Mohamed I. El Gohary*, Salwa A. Abdelkawi**, Aziza A. Hassan***, Ahmed TS Saif**** and Ayman S. El Shinawy*.

*Physics Department, Biophysics Branch, Faculty of Science, Al-Azhar University (Boys); **Department of Vision Science, Biophysics and Laser Science Unit, Research Institute of Ophthalmology; ***Ophthalmic Unit, National Institute for Laser Enhanced Science, Cairo University, ****Ophthalmology Department, Fayoum University, Egypt.

THE AIM of the present work is to evaluate the effect of photodynamic therapy (PDT) by using argon laser with rose bengal (Herbs) as a photosensitizer when compared to the Avastin for treatment of corneal neovascularization (CNV) in rabbits. Thirty-Nine Newzealand male rabbits aged 2.5 months and weighing 2.5-3 kg are selected from the animal house of research institute of ophthalmology, Giza, Egypt. Three rabbits are considered as control, and thirty-six rabbits are subjected to corneal neovascularization (CNV) induced by 3 silk sutures at mid-stromal depth approximately 1 mm from the limbus. After four days, sutures are removed and slit lamp examinations are performed to determine the area of CNV. Rabbits with CNV are divided into 3 groups: (1) The first group left without any treatment (n=12); (2) The second group (n=12 rabbits) were generally anesthetized and rose bengal (C₂₀H₄Cl₄I₄O₅) with a dose of 50 mg/Kg was administered by slow intravenous injection in the marginal ear vein. After 15 minutes, rabbit's eyes were exposed to argon laser (Quantel-Medical, Vitra, France) in a pulsed mode at 532 nm, spot size of 50 μm, pulse duration of 0.2 ms and a power of 150-200 mW/cm²; (3) The third group has been treated with subconjunctival injection of 25 mg Avastin (n=12). The rabbits were followed up for 4 weeks and 3 rabbits are selected and sacrificed weekly from each group. The corneas have been isolated for determination of protein content, SDS-poly acrylamide gel electrophoresis, total antioxidant capacity (TAC) and total oxidative capacity (TOC). Final results show that avastin is almost as effective as photodynamic therapy.

Keywords: Corneal neovascularization (CNV) , Photodynamic therapy (PDT), Argon laser , Avastin.

The eye is a vital organ which gives us the sense of sight, allowing us to learn more about the surrounding world than we do with any of the other four senses. Cornea is the outermost part of the eye. It is clear with no blood vessels to nourish it but it obtains its nourishments from the tear and aqueous humor. It is an organized group of cells and proteins arranged in five layers⁽¹⁾. It provides two-thirds of the total ocular refractory power. Corneal neovascularization (CNV) is considered as one of the most common cause of blindness worldwide⁽²⁾. Corneal neovascularization (CNV) is a challenging condition, and because corneal clarity and avascularity are critical for maintaining vision, developing treatments for corneal NV is crucial. Corneal NV occurs as a result of disequilibrium between angiogenic and

antiangiogenic stimuli^(3,4). Many different types of treatment have been tried previously for corneal neovascularization. The primary treatments of these vessels are the topical corticosteroids and non-steroids anti-inflammatory drugs. However, if the vessels have been established for an extended period, these treatments are ineffective⁽⁵⁾. In photodynamic therapy, systemically administered porphyrin derivatives accumulate in proliferating endothelial cells. Laser energy is then used to activate the porphyrin derivatives liberating cytotoxic oxygen free radicals⁽⁶⁾. This reactive oxygen species (ROS) facilitate the damage of vascular endothelium by activates platelets, leading to the formation of thrombus that occlude the target vessels. Vascular endothelial growth factor (VEGF) is a member of the platelet-

*Corresponding author :ayman_salah8@yahoo.com

DOI: 10.21608/EJBEE.2018.2840.1014

©2017 National Information and Documentation Centre (NIDOC)

derived growth factor (PDGF) family. The VEGF gene family is constituted of VEGF-A, B, C, D and placenta growth factor (PlGF), located on chromosome 6p12⁽⁷⁾. VEGF is thought to cause increment of vascular permeability by formation of fenestrations in microvascular endothelium⁽⁸⁾. Inhibition of VEGF activity is key to treatment of macular edema and prevention of progressive capillary non-perfusion, especially in diabetic retinopathy and retinal vein occlusions. Avastin is a humanized monoclonal antibody that binds to isoforms of VEGF-A⁽⁹⁾. Avastin was initially approved for the treatment of metastatic colorectal cancer; however, it has since been used off-label to treat a variety of ophthalmic conditions, including neovascular age-related macular degeneration, diabetic retinopathy, central retinal vein occlusion, and neovascular glaucoma⁽¹⁰⁾. The present work aims to examine the efficacy of photodynamic therapy (PDT) when compared to the Avastin for treatment of corneal neovascularization (CNV) in rabbit's eye.

Materials and Methods

Thirty-Nine Newzealand male rabbits aged about 3 months and weighing 2.5 - 3 kg are selected from the animal house of research institute of ophthalmology, Giza, Egypt. The rabbits are maintained in a standard 12 hr light-dark cycle with free access to water and balanced diet at a temperature of $22 \pm 2^\circ\text{C}$ and 50% humidity. All rabbits' eyes are examined by slit lamp biomicroscope before induction of corneal neovascularization. All procedures are conducted according to the principles enunciated in the guide for care and use of laboratory animals. They are subjected to experimental protocols approved by the local experimental ethical committee of ophthalmic and vision research.

Slit lamp examination

All rabbits' eyes are examined by slit lamp biomicroscope before induction of corneal neovascularization. The results indicate that there are no signs of edema, corneal neovascularization or intraocular inflammation in all eyes.

Corneal neovascularization procedure

Three rabbits are used as control, and thirty-six rabbits (n=72 eyes) were generally anesthetized using intramuscular Xylaject (0.2 ml/kg) and ketamine hydrochloride (0.6 ml/kg). Benoxinate eye drops (0.4%) is used for local anesthesia. Corneal neovascularization is induced by a three-interrupted 7.0 silk sutures at

a mid-stromal depth approximately 1 mm from the limbus⁽¹¹⁾ (**Fig. 1**). Anti-inflammatory eye drops (Diclofenac) was used three times daily to treat pain and inflammation. After four days' sutures were removed and slit lamp examinations were performed to determine the area of corneal neovascularization.

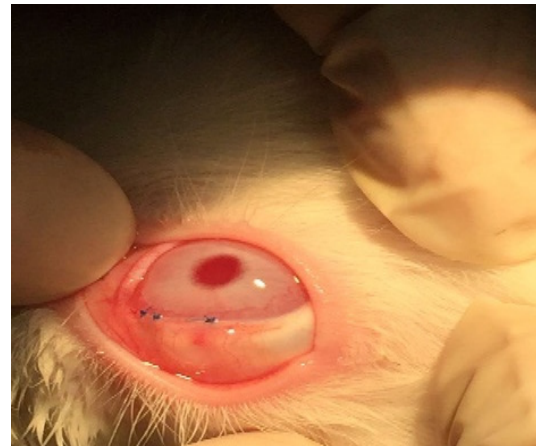


Fig.1. Three sutures in the rabbit's eye to induce corneal neovascularization.

The rabbits are divided into 3 groups as follows:

Group with corneal neovascularization
(n=12 rabbits).

Group treated with photodynamic therapy

(n=12 rabbits) are generally anesthetized and rose bengal with a dose of 50 mg/kg is administered by slow intravenous injection in the marginal ear vein. After 15 minutes, rabbits' corneas are exposed to argon laser (Quantel-Medical, Vitra, France) at 1 cm distance from the cornea in a continuous mode of exposure at 532 nm for 5 minutes and a power of 150 mW/cm² (Ophthalmology department, national institute of laser enhanced science, Cairo University, Egypt).

Group treated with Avastin

(n=12 rabbits), the rabbits are subjected to subconjunctival injection of 25 mg /eye avastin (Genentech Inc., San Francisco, CA). For a follow up period of 1, 2, 3 and 4 weeks, 3 animals are selected weekly from each group, sacrificed, and the eyes are enucleated.

The corneas are removed carefully from the anterior chamber and the neovascularized portions of the corneas are isolated and accurately weighed and homogenized using cell homogenizer (type Tübingen 7400, Germany), in a 10- fold

volume of 20 mM ice-cold tris-HCl buffer, pH 7.4. The homogenate is centrifuged for 20 minutes at 10,000 rpm in a bench centrifuge (Avel centrifuge MS 20, France). The resultant supernatant is used for determination of total protein content, SDS-PAGE, total antioxidant capacity (TAC) and total oxidative capacity (TOC). All reagents are of the highest purity available. Chemicals for measurement of TAC and TOC were purchased from Sigma Chemical Co. (St. Louis, MO).

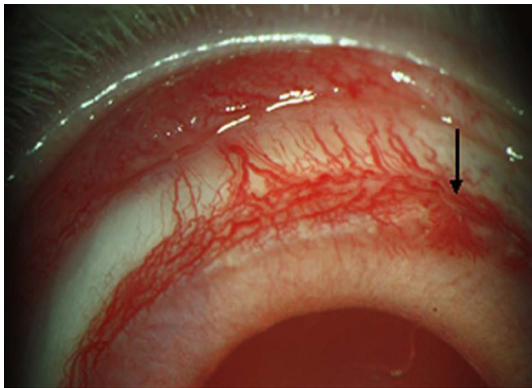


Fig. 2. Corneal neovascularization formation after removing the sutures.

Protein analysis

Corneal total protein content is determined according to the method of Lowry et al. (1951)⁽¹²⁾. The developing color was measured with a spectrophotometer (type UV-visible recording 240 Graphical, Shimadzu, Japan) at 750 nm. Protein composition of the cornea is analyzed by SDS – Polyacrylamide Gel Electrophoresis (PAGE) according to its molecular weight by the method of Laemmli (1970)⁽¹³⁾ using 3 % stacking gel and 10 % separating gel.

Total antioxidative capacity (TAC)

The supernatants are subjected to biochemical

analysis of the total antioxidative capacity using a colorimetric method performed by the reaction of antioxidants in the sample with a defined amount of exogenously provided hydrogen peroxide (H_2O_2). The TAC is determined at 505 nm by an enzymatic reaction and the results are expressed in terms of mM/g tissue⁽¹⁴⁾.

Measurement of total oxidant capacity (TOC)

The TOC levels of the cornea are determined using a colorimetric method⁽¹⁵⁾. The color intensity measured spectrophotometrically at 510 nm, is related to the total number of oxidant molecules present in the sample. The results are expressed in terms of mM/g tissue⁽¹⁶⁾.

Statistical analysis

Statistical analysis is performed using Student's t-test. The results are expressed as the mean \pm standard deviation (SD). Statistical significance is assumed at a level of $p < 0.05$.

Results

Total Protein Content

Figure 3 summarizes the change in the total protein content of the cornea after treatment of corneal neovascularization with Avastin and PDT. The total protein content for the control cornea is 91.12 ± 0.04 mg/g tissue increased to 116.86 ± 0.12 mg/g tissue after four weeks of corneal neovascularization induction, with a percentage change of approximately 28.25%. There was gradual improvement over the four weeks in the treated groups with both Avastin and PDT until the total protein content significantly decrease to 91.43 ± 0.08 mg/g tissue and 91.16 ± 0.05 mg/g tissue with a percentage change of 0.34 % and 0.04 %, respectively.

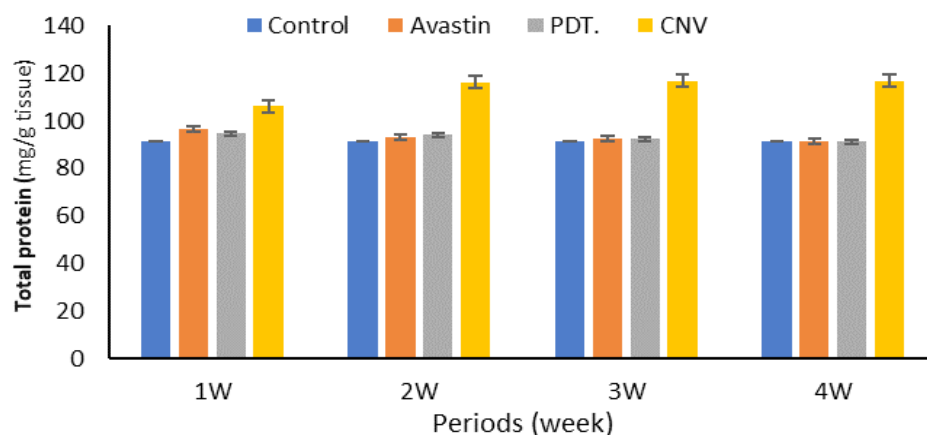


Fig. 3. Total soluble protein content for the control group, CNV group, PDT group and Avastin treated group after 1, 2, 3, and 4 weeks.

SDS-PAGE for corneal protein

Figure 4 shows the SDS-polyacrylamide gel electrophoresis scanning pattern of the corneal

protein after 1 week for different groups as compared with the control group.

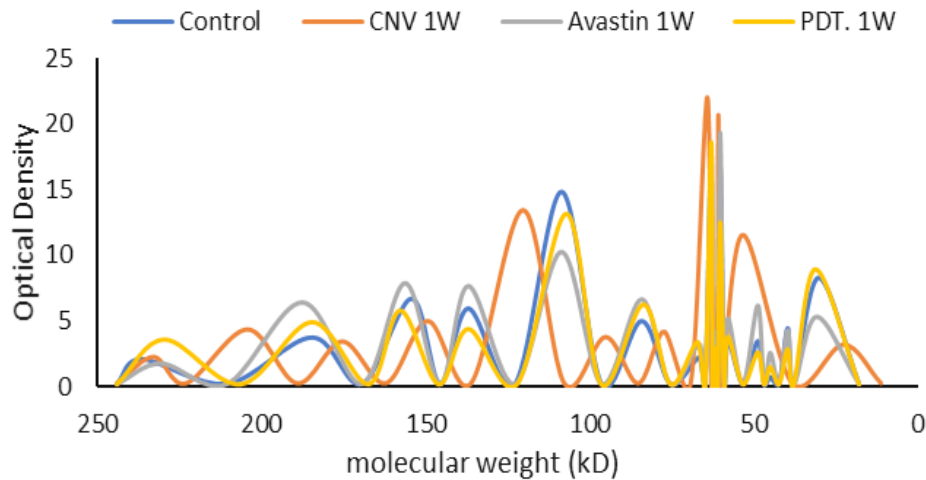


Fig. 4. SDS-electrophoresis scanning patterns, for the control group, CNV, PDT and Avastin treated group after 1 week.

The control pattern is characterized by presence of 14 peaks that varies in their molecular weights, broadening and intensities. After one week, the pattern shows a decrease in the number of peaks in the CNV group where it becomes 11 peaks in addition to the change in the molecular weights in most of the constituent peaks. The disappearance of peaks is in the region between 40 kD and 50 kD and peak at 137 kD. Although there is no noticeable change in number of peaks for the two groups treated with Avastin and PDT, but there are slight changes in the molecular weights and optical density.

After two weeks, the electrophoretic pattern shows progressive change in the molecular weight and optical density for the CNV group as compared with the control. In addition, as shown in Fig. 5, a good improvement is observed in the molecular weight and optical density after treatment with Avastin and photodynamic therapy (PDT).

Moreover, after 3 weeks (Fig. 6), for the CNV group there is a clear difference in both molecular weight and optical density for many fractions if compared with the control group. Additionally, the improvement in photodynamic therapy (PDT) group is slightly better than the improvement in the group treated by Avastin.

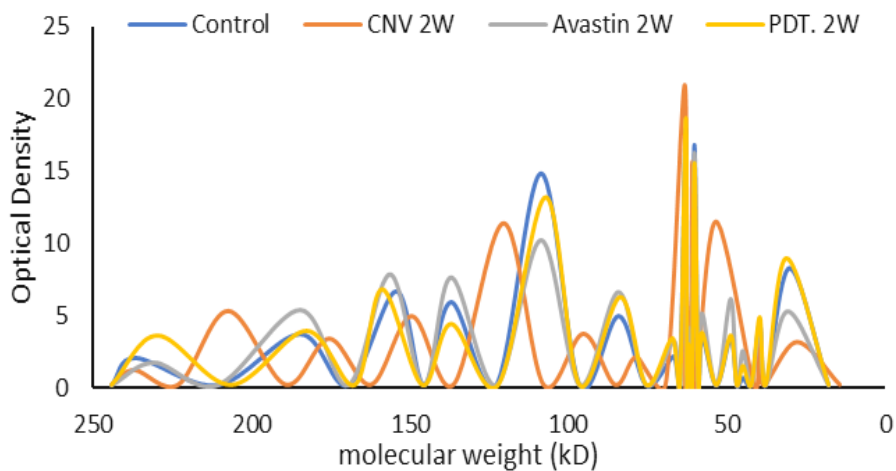


Fig. 5. SDS-electrophoresis scanning patterns of the cornea for the control group, CNV, PDT and Avastin treated group after 2 weeks.

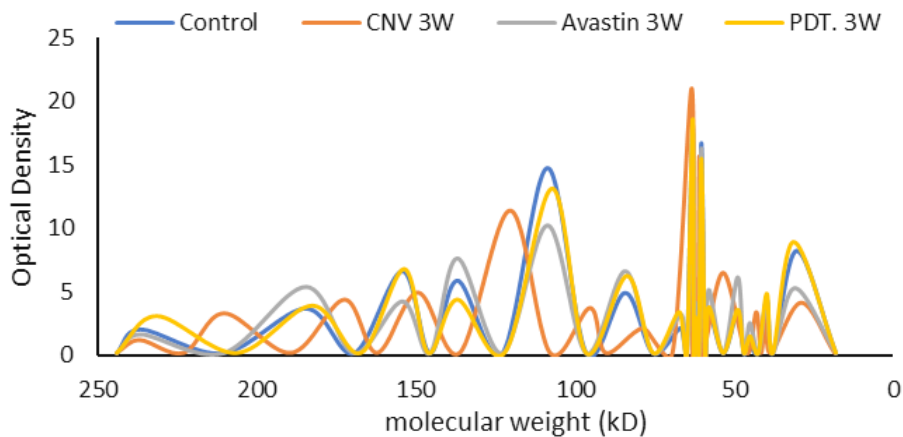


Fig. 6. SDS- electrophoresis scanning patterns for the cornea measured after 3weeks for the control group, CNV, PDT and Avastin treated group.

Furthermore, after 4 weeks, a comparison is made for the control group and the other three groups. As appears, in Fig.7, the SDS-electrophoresis scanning patterns indicated that there is a significant improvement in both groups which are treated with photodynamic therapy (PDT) and the other group that treated by Avastin. Otherwise, there is a marked difference in both the number of peaks, molecular weight, and optical density in the corneal neovascularization (CNV) group if compared with the control group. The CNV pattern is characterized by presence of 15 peaks. This means that the number of peaks in this group exceed the number of peaks of the control group in addition to the formation of 3 peaks in the region between 30 kD to 80 kD.

Total antioxidant capacity (TAC)

Figure 8 presents the TAC for the control cornea as compared with the neovascularized in addition to the treated groups. The TAC for the control is 0.072 ± 0.002 mM/g tissue, and significantly decreases to 0.058 ± 0.001 mM/g tissue, in the CNV after four weeks with a percentage change of 19.49 % ($P < 0.001$). Moreover, TAC shows gradual improvement after 1, 2, 3, and 4 weeks for all treated groups. The total antioxidant capacity after four weeks is 0.072 ± 0.003 and 0.074 ± 0.003 (mM/g tissue) for the PDT and Avastin groups, respectively. In addition, when comparing the percentage change with the control, it is 0.12 % ($P > 0.05$) for PDT and 2.59 % ($P < 0.05$) for Avastin treated group.

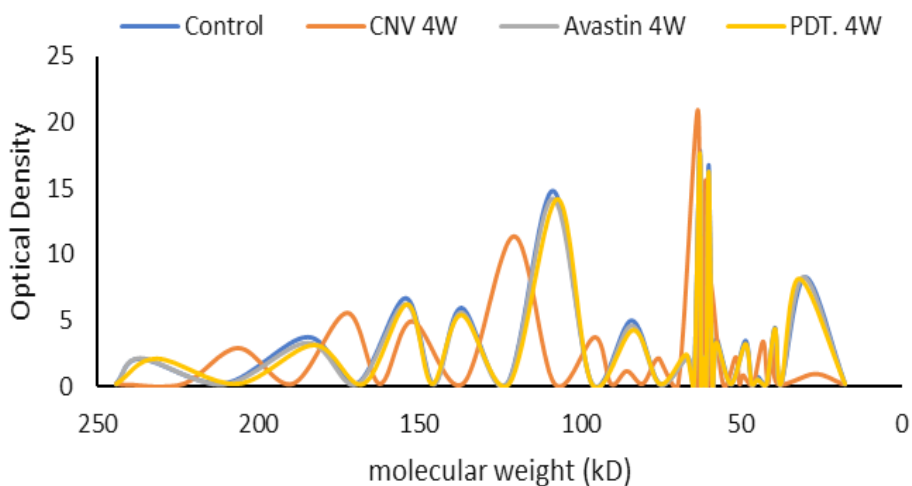


Fig. 7. SDS-electrophoresis scanning patterns for the cornea of rabbits are obtained after four weeks for different groups as compared with the control group.

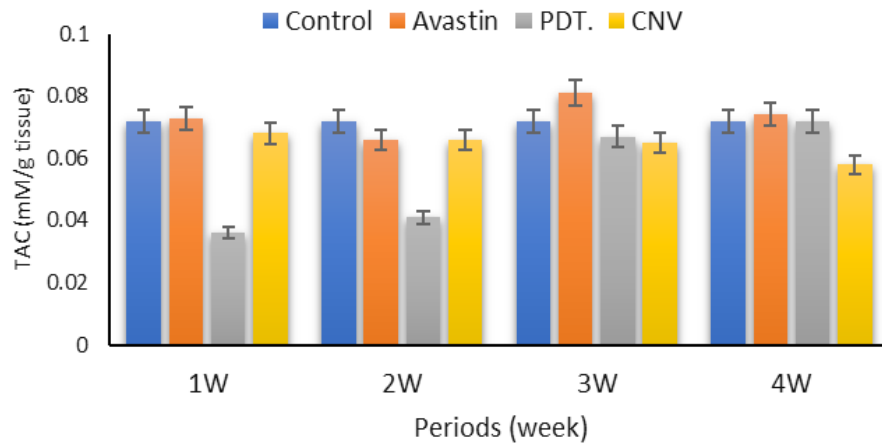


Fig. 8. Total antioxidant capacity for the control group, CNV, PDT and Avastin treated groups after 1, 2, 3, and 4 weeks.

Total oxidative capacity (TOC)

Figure 9 summarizes the total oxidative capacity (TOC) for the control group, CNV, PDT and Avastin treated groups after 1, 2, 3, and 4 weeks.

TOC for the control cornea is 20.56 ± 0.17 mM/g tissue, this value shows gradual increase in the corneal neovascularized group (CNV) during the follow up time to 29.60 ± 0.08 mM/g tissue with a percentage change of 43.97 % ($p < 0.001$). The results show that the total oxidative capacity after four weeks are 20.38 ± 0.06 mM/g and 20.59 ± 0.16 mM/g tissue within the PDT group and Avastin group, respectively.

In addition, improvement in PDT group is similar to the Avastin treated group with a percentage change of 1.17 % and 0.15%, respectively.

Discussion

Photodynamic therapy (PDT) is a method of treatment concerning with the selective accumulation of photosensitizing compound in the hyperproliferative target cells followed by local irradiation of lesion with visible light. Recently, photodynamic therapy has gained increasing interest in ophthalmology, representing an experimental tool for the diagnosis and treatment of abnormal tumors located in the eye. The combination of drug and light, in the presence of oxygen results in the selective destruction of the target tissue by necrosis and apoptosis according to the results obtained by *Lukšienė, 2003*⁽¹⁷⁾. Several investigations reinforced the idea that the efficiency of PDT is related to the yield of oxygen in the environment of the tumor and its

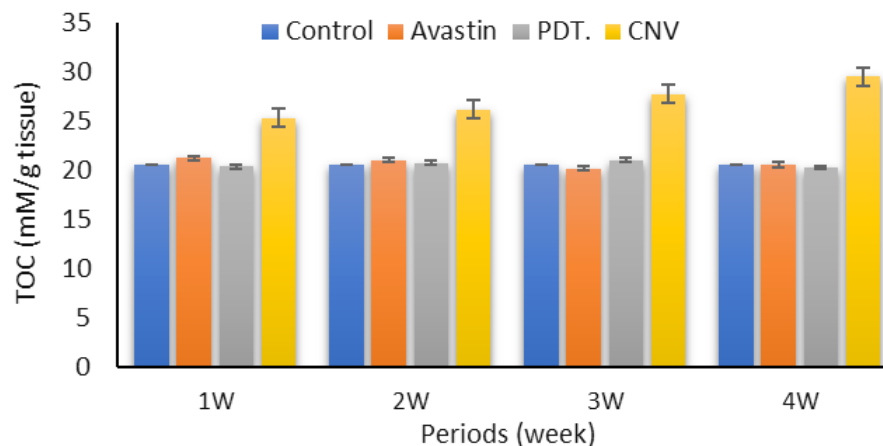


Fig. 9. Total oxidative capacity for the control group, CNV, PDT and Avastin treated groups after 1, 2, 3, and 4 weeks.

yield depends on the concentration of oxygen in the tissue. Hypoxic cells are very resistant to photosensitization and the photodynamic reaction mechanism may consume oxygen at a rate sufficient to inhibit further photosensitization effects. It has been suggested, that hyperbaric oxygen might enhance the photosensitization effect according to **Henderson and Dougherty, 1992** ⁽¹⁸⁾. Recently, the topical use of Avastin as well as subconjunctival injection has also been considered as a new treatment modality for corneal NV according to the results obtained by **Uy, 2008 and Bahar, 2008** ^(19,20) Topical Avastin is demonstrated to inhibit corneal NV after chemical injury in an experimental rat model according to the results obtained by **Manzano et al., 2007**. ⁽²¹⁾ In human, a small number of studies show that topical bevacizumab (Avastin) can reduce corneal NV in a few patients with significant corneal NV according to **Kim et al., 2008 and DeStafeno et al., 2007**.^(22,23) The purpose of this study is to report the efficacy of treating experimental corneal NV in rabbits by using photodynamic therapy as compared with subconjunctival injection of Avastin. In the present study, the change in corneal protein after induction of NV is evaluated. The results indicate elevated levels of corneal protein percentage above the baseline of the control (28.25%). Furthermore, decreasing in protein content is observed during the next four weeks after exposure to PDT and treatment with Avastin due to regression of corneal NV. These results suggest that, the induction of corneal NV caused corneal hypoxia, inducing the formation of new vascular growth by increasing the activity of VEGF (*The Association for Research in Vision and Ophthalmology ARVO, 2008*). This process is associated with an enhanced formation of blood vessels containing blood component, leading to elevated levels of protein content of the cornea and therefore changing in its SDS-electrophoresis pattern. Furthermore, once rose bengal is activated by argon laser in the presence of oxygen, highly reactive, short-lived singlet oxygen and ROS are generated. Laser activation of rose bengal resulted in local damage to neovascular endothelium, vessel occlusion, leading to gradual improvement in protein content and in electrophoresis patterns during the next four weeks after PDT, indicating the suppression of vessels growth and the survival of corneal tissue. It is well known that various antioxidants have an additive effect, protecting the organism from free radicals according to **Wayner et al., 1987** ⁽²⁴⁾. In this regard, evaluation

of TAC and TOC provides information about the antioxidative and oxidative capacity of the tissues according to the results obtained by **Erel, 2004** ⁽²⁵⁾. The present study evaluates the levels of TAC and TOC of neovascularized cornea and cornea exposed to PDT or treated with Avastin. Reactive oxygen species (ROS) are produced in metabolic and physiological processes, and harmful oxidative reactions may occur in organisms that remove them *via* enzymatic and non-enzymatic antioxidative mechanisms. Unstable free radical species attack cellular components causing damage to lipids, proteins, and DNA, which can initiate a chain of events resulting in the onset of a variety of diseases. Furthermore, living organisms have developed complex antioxidant systems to counteract ROS and to reduce their damage according to **Yanik et al., 2004, Erel, 2005, and Yeni et al., 2005** ⁽²⁶⁻²⁷⁻²⁸⁾. These antioxidant systems include enzymes such as superoxide dismutase, catalase, and glutathione peroxidase; macromolecules such as albumin, ceruloplasmin, and ferritin; and an array of small molecules, including ascorbic acid, α -tocopherol, β -carotene, reduce glutathione, uric acid, and bilirubin. The sum of endogenous and food-derived antioxidants represents the total antioxidant activity of the system. The cooperation among different antioxidants provides greater protection against attack by reactive oxygen or nitrogen species, than any single compound alone. Thus, the overall antioxidant capacity may provide more relevant biological information as compared to that obtained by the measurement of individual components, as it considers the cumulative effect of all antioxidants present in tissues according to **Koracevic et al., 2001** ⁽¹⁴⁾. Oxidative stress results from increased number of lipid and protein oxidation products and decreased number of antioxidant enzymes and vitamins according to the results obtained by **Koksal and Kurban, 2010** ⁽²⁹⁾. The present study exhibits a decrease in the TAC and increase in TOC of the cornea after induction of corneal NV. Furthermore, PDT stimulates the antioxidant defense system by elevation of TAC because it induces more oxidative stress. These data indicated that PDT using rose bengal and argon laser, show a stronger cytotoxicity to neovascular endothelium that observed after one week of laser treatment. Furthermore, since this toxic effect of PDT appears is time dependent, the results indicate gradual improvement of the cornea after the 3rd and 4th week of PDT.

The obtained results suggest that the

oxidative/antioxidative balance shifts towards the antioxidative status and PDT causes growth cycle arrest that helps to prevent further damage and give the cell time to repair the defect. These results agree with previous reports of *Nowak-Sliwinska et al., 2006*⁽³⁰⁾ and *Chan et al., 2010*⁽³¹⁾. They concluded that, damaged endothelium is known to release procoagulant and vasoactive factors through the lipo-oxygenase (leukotriene) and cyclo-oxygenase (eicosanoids such as thromboxane) pathways, resulting in platelet aggregation, fibrin clot formation and vasoconstriction. In addition, the antiproliferative activities would be not due to direct toxicity against neovascularized cells but due to blocking of some proliferative steps according to the results obtained by *Bortner and Cidlowski, 2002*⁽³²⁾.

Conclusion

Corneal angiogenic factors include vascular endothelial growth factor (VEGF), with studies showing that VEGF activation can induce corneal NV, and that inhibition of VEGF can block new vessel formation in animal cornea model.

- Anti-VEGF therapy is considered as a possible tool for controlling NV.
- Avastin shows an inhibitory effect on CNV in rabbits' eyes. Photodynamic therapy (PDT) with a photosensitizer can induce microvascular thrombosis with minimal damage to the surrounding normal tissue.
- Activation of the photosensitizer (rose bengal) by argon laser energy releases highly reactive, cytotoxic, short-lived singlet oxygen and other reactive oxygen radicals. This leads to endothelial cell damage and vascular leakage, coagulation, and thrombocyte aggregation, which trigger neovascular vessel occlusion.
- PDT with rose bengal is also effective in decreasing the corneal blood vessels.
- Final results of all measurements show a gradual improvement over the different periods and a significant similarity in the efficacy of both argon laser and vascular chemotherapy of the rabbit cornea using avastin.

References

1. Vaishya RD, Khurana V, Patel S, Mitra AK., Controlled ocular drug delivery with nano micelles: *Wiley Interdiscip Rev Nanomed Nanobiotechnol*, **6(5)**, 422 – 437 (2014).
2. Faraj LA, Said DG, Dua HS., Evaluation of corneal neovascularization: *Br J Ophthalmol*; **95**, 1343 -1344 (2011).
3. Chang JH, Gabison EE, Kato T, Azar DT., Corneal neovascularization: *Curr Opin Ophthalmol*, **12**, 242 – 249 (2001).
4. Azar DT., Corneal angiogenic privilege: angiogenic and antiangiogenic factors in corneal a vascularity, vasculogenesis, and wound healing (an American Ophthalmological Society thesis): *Trans Am Ophthalmol Soc* **104**: 264 – 302 (2006).
5. Epstein R. J., Stulting R. D., Hendricks R. L., Harris D. M., Corneal neovascularization: Pathogenesis and inhibition: *Cornea* **6**, 250–257 (1987).
6. Gohto Y, Obana A., Kanai M., Nagata S., Miki T, Nakajima S., Photodynamic therapy for corneal neovascularization using topically administered ATX-S10 (Na): *Ophthalmic Sur: Lasers*, **31**, 55 – 60 (2000 b).
7. Pasqualetti G, Danesi R, Del Tacca M, Bocci G., Vascular endothelial growth factor pharmacogenetics: a new perspective for anti-angiogenic therapy: *Pharmacogenomics*, **8(1)**, 49-66 (2007).
8. Roberts WG, Palade GE., Neovasculature induced by vascular endothelial growth factor is fenestrated: *Cancer Res*, **57(4)**, 765 - 772 (1997).
9. Ferreira SM, Lerner SF, Brunzini R, Evelson PA, Llesuy SF. Oxidative stress markers in aqueous humor of glaucoma patients: *Am J Ophthalmol*, **137**, 62 – 69 (2004).
10. Iliev ME, Domig D, Wolf Schnurrbursch U, Intravitreal bevacizumab (Avastin) in the treatment of neovascular glaucoma: *Am J Ophthalmol*, **14**, 1054 -1056 (2006).
11. Schmidt-Erfurth U., Hasan T., Schomacker K., Flotte T., Birngruber R., In vivo uptake of liposomal benzoporphyrin derivative and photothrombosis in experimental corneal neovascularization: *Laser Surg. Med.*, **17**, 178–188 (1995).
12. Lowry O. H., Rosebrough N. J., Farr A. L., Randall R. J., Protein measurements with the folin phenol reagent: *J. Biol. Chem.* **193**, 265–275 (1951).
13. Laemmli U. K., Cleavage of structural proteins during the assembly of the head of bacteriophage T4: *Nature* **227**, 680 – 685 (1970).
14. Koracevic D., Koracevic G., Djordjevic
Egypt. J. Biophys. Biomed. Engng. Vol. 18 (2017)

- V., Andrejevic S., Cosic V., Method for the measurement of antioxidant activity in human fluids: *J. Clin. Pathol.* **54**, 356 – 361(2001).
15. Aebi H., Catalase in vitro: *Methods Enzymol.* **105**, 121–126 (1984).
16. Demirbag R., Gur M., Yilmaz R., Kunt A. S., Erel O., Andac M. H. Influence of oxidative stress on the development of collateral circulation in total coronary occlusions. *Int. J. Cardiol.* **116**, 14–19 (2007).
17. Lukšienė Ž., Photodynamic therapy: mechanism of action and ways to improve the efficiency of treatment: *Medicina* **39**, 1137–1150 (2003).
18. Henderson B. W., Dougherty T. J., How does photodynamic therapy work? *Photochem. Photobiol.* **55**, 145–157 (1992).
19. Uy HS, Chan PS, Ang RE., Topical bevacizumab and ocular surface neovascularization in patients with stevens-johnson syndrome: *Cornea.*, **27(1)**, 70 – 73 (2008).
20. Bahar I, Kaiserman I, McAllum P, et al., Subconjunctival bevacizumab injection for corneal neovascularization: *Cornea.*, **27(2)**, 142–147 (2008).
21. Manzano RP, Peyman GA, Khan P, et al., Inhibition of experimental corneal neovascularization by bevacizumab (Avastin): *Br J Ophthalmol.*, **91(6)**, 804–807 (2007).
22. Kim SW, Ha BJ, Kim EK, et al., The effect of topical bevacizumab on corneal neovascularization: *Ophthalmology*, **115(6)**, e33 – e38 (2008).
23. DeStafeno JJ, Kim T., Topical bevacizumab therapy for corneal neovascularization: *Arch Ophthalmol.*, **125(6)**, 834 – 836 (2007).
24. Wayner D. D., Burton G. W., Ingold K. U., Barclay L. R., Locke S. J., The relative contributions of vitamin E, urate, ascorbate and proteins to the total peroxy radical-trapping antioxidant activity of human blood plasma: *Biochem. Biophys. Acta* **924**, 408 – 419 (1987).
25. Erel O. A novel automated method to measure total antioxidant response against potent free radical reactions: *Clin. Biochem.* **37**, 112–119 (2004).
26. Yanik M., Erel O., Kati M., The relationship between potency of oxidative stress and severity of depression: *Acta Neuropsychiatr.* **16**, 200–203 (2004).
27. Erel O. A new automated colorimetric method for measuring total oxidant status. *Clin. Biochem.* **38**, 1103 – 1111(2005).
28. Yeni E., Gulum M., Selek S., Erel O., Unal D., Verit A., Savas M., Comparison of oxidative/antioxidative status of penile corpus cavernosum blood and peripheral venous blood. *Int. J. Impot. Res.* **17**, 19–22 (2005).
29. Koksall H., Kurban S., Total oxidant status, total antioxidant status, and paraoxonase and arylesterase activities during laparoscopic cholecystectomy: *Clinics* **65**, 285–290 (2010).
30. Nowak-Sliwinska P., Karocki A., Elas M., Pawlak A., Stochel G., Urbanska K., Verteporfin, photofrin II, and merocyanine 540 as PDT photosensitizers against melanoma cells: *Biochem. Biophys. Res. Commun.* **349**, 549 – 555 (2006).
31. Chan W. M., Lim T. H., Pece A., Silva R., Yoshimura N. Verteporfin PDT for non-standard indications – a review of current literature. *Graefes Arch. Clin. Exp. Ophthalmol.* **248**, 613–626 (2010).
32. Bortner C. D., Cidlowski J. A., Cellular mechanisms for the repression of apoptosis: *Ann. Rev. Pharmacol. Toxicol.* **42**, 259 – 281 (2002).

فعالية ليزر الارجون والعقار بيفاسيزيوماب (افاستين) في علاج الاوعية الدموية المستحدثة بالقرنية في النماذج الحيوانية التجريبية

محمد اسماعيل الجوهري ، سلوى عبد القوي احمد عبد القوي ، عزيزة احمد حسن ، احمد تامر سيد سيف و ايمن صلاح الدين الشناوي

قسم الفيزياء – شعبة الفيزياء الحيوية – كلية العلوم (بنين) – جامعة الازهر – مدينة نصر ، قسم الفيزياء الحيوية وعلوم الليزر - معهد بحوث امراض العيون – الجيزة ، المعهد القومي لعلوم الليزر - جامعة القاهرة وقسم امراض العيون – كلية الطب – جامعة الفيوم ، قسم الفيزياء – شعبة الفيزياء الحيوية – كلية العلوم (بنين) – جامعة الازهر – مدينة نصر – القاهرة.

العين هي أحد أهم الأعضاء الموجودة بجسم الكائن الحي والتي يمكن من خلالها رؤية الأجسام المختلفة، وتعتبر القرنية من أهم الأجزاء المُكوِّنة للعين باعتبارها المُستَقْبِل الأول للضوء الساقط على العين والتي من خلالها يُمكن إتمام عملية رؤية الأجسام. وتقوم القرنية بتجميع الضوء في نقطة واحدة على سطح الشبكية بمساعدة العدسة البلورية للعين. وتتميز القرنية بأنها شفافة اللون وذلك لعدم إحتوائها على أي أوعية دموية حتى وإن كانت صغيرة ولذا فإنها تحصل على غذائها من الدموع وتحصل أيضا على الأكسجين مباشرةً من الهواء الجوي وهذا يُساعد في رؤية الأجسام بشكل واضح ودقيق. ظهور أي أوعية دموية في القرنية حتى وإن كانت صغيرة جداً يؤدي إلى إحصار وألم مُتزايد في العين وحساسية شديدة للضوء وهذا قد يُؤثر سلباً في عملية الرؤية السليمة وجِدَّة الإبصار. وقد أجريت هذه الدراسة لتقييم فعالية كلا من الأرجون ليزر والعقار أفاستين في علاج الأوعية الدموية المستحدثة بالقرنية (Corneal neovascularization) في الأرانب. وقد تم إجراء هذه الدراسة على ثلاث مجموعات بالإضافة إلى المجموعة الضابطة، وتم تقسيم كل مجموعة من الأرانب على فترات محددة وذلك لرصد مدى التغيير الحادث خلال تلك الفترات بعد 4،3،2،1 أسابيع.

وهذه المجموعات كما يلي:

- مجموعة مُصابة ولم يتم علاجها (CNV group).
- مجموعة تم علاجها باستخدام الأرجون ليزر بعد الإصابة (PDT. group).
- مجموعة تم علاجها باستخدام عقار الأفاستين بعد الإصابة (Avastin group).

وبعد تجميع العينات من جميع المجموعات خلال الفترات المختلفة تم إجراء القياسات التالية:

- حساب تركيز البروتينات الكلية الموجودة بالقرنية (Total Protein content) (T.P.C).
- تعيين تركيز مضادات الأكسدة الكلية الموجودة بالقرنية (TAC).
- تعيين تركيز المواد المؤكسدة الكلية الموجودة بالقرنية (TOC).
- قياس التغيير في الوزن الجزيئي لبروتينات القرنية عن طريق الفصل الكهربائي للبروتين باستخدام جهاز (Electrophoresis) (SDS-PAGE).

وقد أظهرت النتائج النهائية لجميع القياسات حدوث تحسن تدريجي خلال الفترات المختلفة ووجود تشابه كبير في مدى فاعلية كلاً من الأرجون ليزر والعلاج الكيميائي للأوعية الدموية المستحدثة بقرنية الأرانب باستخدام عقار الأفاستين.

- ويمكن إيجاز النتائج النهائية كما يلي:
- عندما تم حساب تركيز البروتين الموجود بقرنية العين في المجموعات المختلفة ومقارنته بالمجموعة الضابطة (Control group) ظهرت زيادة تدريجية في المجموعة المُصابة والتي لم يتم علاجها (N.V. group)، وهذه الزيادة ترجع إلى وجود الهيموجلوبين داخل الأوعية الدموية المستحدثة بالقرنية والذي يحتوي على نسبة عالية من البروتين. أظهرت النتائج النهائية أيضاً أن استخدام الأرجون ليزر في العلاج أدى إلى نتيجة أفضل قليلاً من الأفاستين.

• بقياس التغيير في الوزن الجزيئي لبروتينات القرنية عن طريق الفصل الكهربائي للبروتين لجميع المجموعات في الفترات المختلفة ورسم النتائج النهائية تبين فعالية كل من الأرجون ليزر والعلاج الكيميائي للأوعية الدموية المستحدثة بقرنية الأرانب باستخدام عقار الأفاستين وقد ظهر ذلك بوضوح تدريجياً من الإِسبوع الأول وحتى نهاية التجربة في الإِسبوع الرابع.